



# WORLD JOURNAL OF CURRENT MEDICAL AND PHARMACEUTICAL RESEARCH

www.wjcmpr.com

ISSN: 2582-0222

## Preventive effect of *Macaranga barteri* Mül Arg. (Euphorbiaceae) aqueous leaf extract on amiodarone induced non-alcoholic fatty liver disease in rats

Goze Nomane Bernard\*, Kouakou Kouakou Léandre, Oussou N'Guessan Jean-Baptiste, Ehile Ehilé Hervé, KOFFI Kouassi Bah Abel, Yapou Angoué Paul

Laboratory of Physiology, Pharmacology and Pharmacopoeia, UFR-SN, Nangui Abrogoua University, (Abidjan, Côte d'Ivoire), 02 BP 801 Abidjan 02, Côte d'Ivoire.

### Abstract

*Macaranga barteri* is a plant used in traditional medicine to treat non-alcoholic fatty liver disease. However, its potential against hepatic steatosis has not been scientifically proven yet. This work aimed to investigate the preventive effect of the aqueous extract of *Macaranga barteri* leaves (AEMb) on hepatic steatosis experimentally induced with amiodarone in rats. 36 rats were divided into 6 groups of 6 rats each. Group 1, the non-intoxicated group and Group 2, used as controls were pretreated with distilled water (10 ml/kg b.w.). Group 3 received silymarin at 100 mg/kg b.w. while Groups 4, 5 and 6 were pretreated with AEMb at doses of 125, 250 and 500 mg/kg b.w. respectively. The weights of the rats were monitored during the experimentation. After 7 days of daily pretreatment with the different substances, rats of groups 2 to 6 were administered intraperitoneally amiodarone (200 mg/kg bw) three times daily for seven other consecutive days. At the end of the experiments, blood samples were collected on fasted and anesthetized rats and kept in dried and EDTA tubes in order to assess some hematological and biochemical parameters. The rat livers were removed for gross observation and hepatic triglyceride assessment. The results revealed that AEMb and silymarin inhibited the weight loss induced by amiodarone and even favored weight gain. The reduction of hematological indices (leukocytes and leukocyte indices, erythrocytes and erythrocyte indices (MCV, MCH and MCHC), hemoglobin, hematocrit and thrombocytes) by amiodarone was impeded in AEMb treated rats. AEMb significantly reduced lipid profile parameters (plasma triglycerides, cholesterols (LDL and total cholesterol) augmented by amiodarone. Increased hepatic parameters (alkaline phosphatase, total and conjugated bilirubins, transaminases (AST and ALT)) elicited by amiodarone were restored by AEMb pretreatment while decreased HDL values were normalized as well. Silymarin and AEMb also restored livers appearance and hepatic triglyceride. In conclusion, AEMb have a real preventive potential against amiodarone induced-hepatic steatosis in rats.

### Article History:



Received: 11.09.2021

Revised: 01.11.2021

Accepted: 14.11.2021

### Keywords:

*Macaranga barteri*, Fatty Liver Disease, Amiodarone, Rat.

### \*Corresponding Author

Name: Goze Nomane Bernard

Email: gozebernard.sn@univ-na.ci

DOI: <https://doi.org/10.37022/wjcmpr.v3i6.197>

This article is licensed under a Creative Commons Attribution-NonCommercial 4.0 International License.

Copyright © 2021 Author(s) retain the copyright of this article.



### Introduction

Non-alcoholic fatty liver disease is as an abnormal accumulation of fatty acids stored as vacuoles in hepatocytes which can be isolated or associated with non-specific liver inflammation [1]. It is one of the leading causes of morbidity and mortality worldwide [2]. Its prevalence in the world varies from 6.3 to 33 % [3]. In Côte d'Ivoire, this prevalence is 4.94 % in patients with metabolic syndrome [4]. Many modern treatments (corticosteroids and immunosuppressants (TNF $\alpha$ )) are used [5]. However, they expose patients to multiple infections [6]. Sometimes, the high cost of these synthetic drugs, their numerous side effects, the health centers insufficiency and inaccessibility and cultural reasons lead a large part of the population, especially in Africa, to use traditional medicine. They are estimated to over 80 % [7]. To promote traditional medicine in order to help the population derive real benefit from it, this study focused on *Macaranga*

*barteri*, a plant used in the treatment of many ailments such as liver injuries [8,9]. This plant was selected because [10] showed that the methanol extract of the trunk bark of this plant has an anti-inflammatory effect on respiratory test cells. To this, [9] showed a strong capacity of the leaf extract to inhibit lipid peroxidation and in addition, this extract would be a potential source of antioxidant. [11] also showed that the aqueous extract of the leaves of this plant exhibited anti-ulcer activities. Therefore, the preliminary study found the leaves to be effective in the treatment of liver injuries.

However, no scientific study has been mentioned the properties of this plant on non-alcoholic fatty liver in rats. Considering the diverse medicinal properties of this plant, the present study was undertaken to evaluate the preventive effect of the aqueous extract of *Macaranga barteri* leaves on non-alcoholic fatty liver experimentally induced with amiodarone in rats.

## Material and Methods

### 1-Materials

#### 1.1- Plant

Fresh leaves of *M. barteri* were harvested from the forest of Nangui Abrogoua University (Abidjan, Côte d'Ivoire). Taxonomic identification of the leaves was established by botanists of Nangui Abrogoua University (Abidjan, Côte d'Ivoire). Thereafter, they were authenticated at National Floristic Center of Felix Houphouët Boigny University (Abidjan, Côte d'Ivoire), with voucher no. 14735 in April 06, 1979 in Côte d'Ivoire National Herbarium.

#### 1.2-Animals

Albino Wistar rats of either sex weighing between 130 and 204 g of approximately 10 to 16 weeks old, were selected for fatty liver disease induced by amiodarone. They were bred in the animal house of Physiology, Pharmacology and Pharmacopeia Laboratory of the University of Nangui Abrogoua (Abidjan, Côte d'Ivoire) according to the principles for the care and use of laboratory animals of the Ethical Committee of the University (Nangui Abrogoua, Abidjan, Côte d'Ivoire). They were exposed to 12 h dark/light cycle and given FACI® pellets for rats and water *ad libitum*. Research was conducted in accordance with the internationally accepted principles for laboratory use and care as found in the European Community Guidelines (EEC Directives of 1986 86/609/EEC) [12].

#### 1.3- Chemical and drugs

The substances used are: Amiodarone (Cordarone®, Sanofi Aventis, France), Ethanol (GATT-KOLLER, Germany), Ether (VWR International-Geldenaakfebaan464-B-3001, Leuven-Belgium), Silymarin (Légalon®, Sanofi Aventis, France).

### 2-Methods

#### 2.1-Preparation of the aqueous leaf extract of *Macaranga barteri*

Fresh leaves of *M. barteri* were harvested, dried at room temperature (22-25 ° C) for one week. Once dried, they were powdered with a grinding machine (RETSCH, type SM 100, Germany). The total aqueous extract was obtained according to the method described by [13]. Thus, one hundred grams (100 g) of the leaf powder of *M. barteri* were decocted in 1 L distilled water for 15 min, filtered (Whatman no. 3) and then stored in desiccators (Mark Fruicell, France) at 45°C for two days. The different concentrations of the extract tested during this experiment were prepared extemporaneously by dissolving the powder obtained in distilled water.

#### 2.2- Experimental design

The method used and slightly modified was described by [14]. Thirty-six fasting rats previously anesthetized with ether, divided into six groups of six rats each, including three males and three females, were all sampled using a Pastor pipette by ocular puncture before being subjected to the various tests (Day 0). Group 1, a non-intoxicated rats group served as negative control, received distilled water at 10 ml/kg b.w. orally once a day for fourteen days. Group 2, (positive control group) was pretreated with distilled water at 10 ml/kg b.w. orally once a day for seven days. The rats of group 3, were pretreated with 100 mg/kg bw of Silymarin, once a day for 7 days orally. Groups 4, 5 and 6, were pretreated with the aqueous extract of *M. barteri* leaves (AEMb) respectively at 125, 250 and 500 mg / kg b.w. *per os* once a day for seven days. After seven days of pretreatment with AEMb and silymarin,

three injections of amiodarone (200 mg/kg) were administered daily by intraperitoneal route to the rats from group 2 to 6 for seven days. Twenty-four hours after the administration of the last dose of amiodarone, i.e. on the 15th day, 2 mL of blood samples from all fasted rat groups were collected in tubes containing an EDTA anticoagulant and in dry tubes, using Pastor pipettes. Hematological parameters (leukocytes and leukocyte indices, erythrocytes and erythrocyte indices (MCV, MCH and MCHC), hemoglobin, hematocrit and thrombocytes) were determined using an automatic analyzer (RAYTO-RT 7600S brand (Japan)). After centrifugation (3000 rpm for 5 min), samples in dry tubes were employed for the assay of the biochemical parameters (alkaline phosphatase, total and conjugated bilirubins, Aspartate Aminotransferase (AST) and Alanine Aminotransferase (ALT), triglycerides, cholesterols (LDL, HDL and total cholesterol) and total proteins) using a Robonik® brand spectrophotometer (India) [15]. The weight of the rats were determined before (Day 0) and at the end (Day 15) of the experiment. The animals were sacrificed by overdose of ether. The liver removed was grossly observed, weighed and treated for the determination of hepatic triglycerides. The relative liver weight was calculated according to the formula of [16].

$$\text{Relative liver weight (\%)} = \frac{\text{liver weight (g)}}{\text{Rat body weight (g)}} \times 100$$

#### 2.3-Statistical analyzes

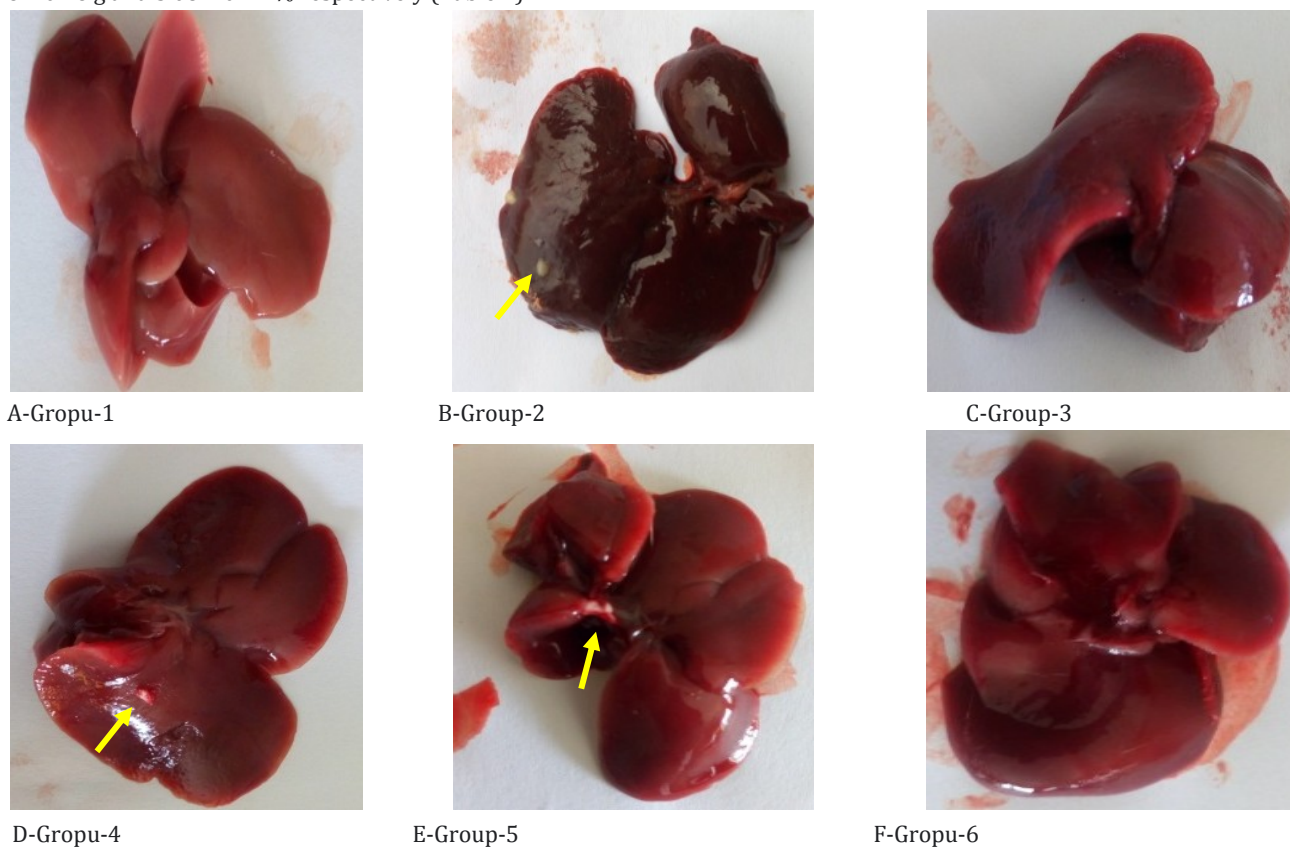
Data were performed using Graph Pad Prism 7.0 software (San Diego, USA) and presented as the mean ± standard error on mean (M ± SEM). Comparisons between treated groups and controls were made using Student's t test and one-way analysis of variance (ANOVA). Tukey-Kramer was used as post-hoc test. Values were considered statistically significant when P < 0.05.

## Results

### 1-Gross observations of the livers and variation in relative weight in rats treated with amiodarone, silymarin and AEMb

The dissection of the liver showed whitish spots, a change in color to blackish red. In Figure 1-A, it was observed normal appearance with light brown color, smooth and firm to the touch in control group 1 rats gavaged only with distilled water. However, animals intoxicated with amiodarone (200 mg/kg bw) had granite, variegated livers with a blackish color containing whitish nodules with soft pasty consistency compared to control group 1 (Figure 1-B). In this group, 83 % of rats presented fat nodules (Table 1). In AEMb pretreated rats (125, 250 and 500 mg/kg b.w.), the livers exhibited granite, brown (figure 1-D) or variegated colors (figure 1-E), with normal consistency, soft and firm to the touch (Figure 1-F) compared to the liver of control group 2 (amiodarone). The rats pretreated with AEMb displayed 16 to 33 % fat nodules (Table 1). In the rats pretreated with silymarin (100 mg/kg b.w.), the livers were light brown, firm to the touch and with normal consistency (Figure 1-C) compared to the livers of control group 2.

Concerning the change in body weight, animals which received only distilled water (group 1) for fourteen days experienced a mean weight change from  $151 \pm 10.1$  to  $164 \pm 3.99$  g i.e. an increase rate of 8.6%, a mean liver weight of  $5.19 \pm 0.45$  g and a relative organ weight of  $3.14 \pm 0.29$  % (Table 2). Unlike control group 1, amiodarone control rats (group 2) experienced a significant decrease ( $p < 0.001$ ) in mean weight from  $161 \pm 8.01$  to  $141 \pm 5.4$  g corresponding to a significant ( $p < 0.001$ ) loss of 12.42 %. The recorded mean weight and relative liver weight were significantly ( $p < 0.001$ ) high compared to those treated only with distilled water and values were  $7.16 \pm 0.26$  g and  $5.08 \pm 0.27$  % respectively (Table 2).



**Figure 1: Photographs of livers of the rats treated with amiodarone, silymarin and AEMb**

Group 1: Distilled water; Group 2 : Distilled water + amiodarone ; Group 3 : silymarin + amiodarone ; Group 4 : AEMb (125 mg/kg b.w) + amiodarone ; Group 5 : AEMb (250 mg/kg b.w) + amiodarone ; Group 6 : AEMb (500 mg/kg b.w) + amiodarone ; yellow arrow indicates the presence of a nodule

**AEMb:** Aqueous extract of *Macaranga barteri* leaves

Table 1: Gross observation of experimental rats

Groups	Change in liver colors	Change in liver appearance	Change in liver consistency	Percentage of liver fat nodules (%)
Control group 1	0	0	0	0
Control group 2	4	5	3	83
Group 3	0	0	1	0
Group 4	2	1	2	33
Group 5	1	1	0	16
Group 6	1	0	0	0

Group 1: Distilled water; Group 2 : Distilled water + amiodarone ; Group 3 : silymarin + amiodarone ; Group 4 : AEMb (125 mg/kg b.w) + amiodarone ; Group 5 : AEMb (250 mg/kg b.w) + amiodarone ; Group 6 : AEMb (500 mg/kg b.w) + amiodarone ; AEMb: Aqueous extract of *Macaranga barteri* leaves; n = 6, number of rats, 0 = none

Table 2: Evolution of the weight growth and relative liver weight of rats pretreated with either AEMb or silymarin

Groups	Initial weight (g)	Final weight (g)	Weight variation percentage (%)	Liver weight (g)	Relative liver weight (%)
Group 1	151±10.10	164±3.99	+8.6	5.19±0.45	3.14±0.29
Group 2	161±8.01	141±5.40	-12.42***	7.16±0.26	5.08±0.27***
Group 3	157±8.03	166±8.93	+5.73###	6.03±0.32	3.60±0.11###
Group 4	145±6.64	161±8.32	+11.03###	6.21±0.39	3.85 ±0.24###
Group 5	152±8.88	175±8.38	+15.13###	6.11±0.33	3.49±0.23 ###
Group 6	175±14.30	201±11	+14.85###	6.19±0.20	3.07±0.10###

\*\*\* $p < 0.001$  significant difference compared to the distilled water control group 1, ###  $p < 0.001$ : significant difference compared to group 2; **AEMb**: aqueous extract of *M. barteri*;  $n = 6$ . Group 1: Distilled water; Group 2: Distilled water + amiodarone; Group 3: silymarin + amiodarone; Group 4: AEMb (125 mg/kg b.w.) + amiodarone; Group 5: AEMb (250 mg/kg b.w.) + amiodarone; Group 6: AEMb (500 mg/kg b.w.) + amiodarone; **AEMb**: Aqueous extract of *Macaranga barteri* leaves

Silymarin and AEMb significantly ( $p < 0.001$ ) reduced the decrease of body weight and the increase in relative liver weight induced by amiodarone. Rats pretreated with silymarin (100 mg/kg b.w.) showed a significant ( $p < 0.05$ ) increase of the weight from  $157 \pm 8.03$  to  $166 \pm 8.93$  g, i.e. a significant ( $p < 0.001$ ) weight gain of 5.73 % compared to control group 2. The liver mean weight was  $6.03 \pm 0.32$  g. As for the mean relative liver weight it was  $3.6 \pm 0.11$  % (Table 2). The value of liver relative weight, which was  $5.08 \pm 0.27$  % in the amiodarone control group, diminished to  $3.07 \pm 0.10$  % at 500 mg/kg b.w. of AEMb (Table 2). AEMb (125-500mg/kg b.w.) increased the weight of rats from 11.03 to 14.85 % (Table 2).

## 2- Effect of the aqueous extract of *Macaranga barteri* leaves on hematological parameters in rats

### 2.1-Effect of different treatments on leukocyte parameters

Oral administration of distilled water for seven days, followed by intraperitoneal intoxication with amiodarone (200 mg/kg b.w.) caused a significant decrease in leukocyte count and leukocyte indices compared to the negative control group 1. Treatment of rats with silymarin (100 mg/kg b.w.) and AEMb at 125, 250 and 500 mg/kg b.w. induced a significant increase ( $p < 0.05$ ) in leukocytes and leukocyte indices compared to control group 2.

Table 3: Effects of different treatments on leukocyte parameters in rats

Leukocyte parameters	Groups					
	group 1	group 2	group 3	group 4	group 5	group 6
Leuco ( $\times 10^3 \mu\text{L}$ )	18.7±1.83	12.7±0.68*	14.5±1.42#	15.2±2.78#	16.5±3.13#	14.6±2.19#
Lympho ( $\times 10^3 \mu\text{L}$ )	13.6±1.33	7.08±2.63**	9.57±1.21#	8.5±1.25#	11.1±1.96##	11.7±0.69###
Mono ( $\times 10^3 \mu\text{L}$ )	1.67±0.18	1.2±0.45*	2.92±1.42#	1.13±0.22#	1.42±0.27#	1.38±0.15##
Neutro ( $\times 10^3 \mu\text{L}$ )	3.4±0.36	1.88±0.19***	2.53±0.49#	4.22±1.35###	3.97±0.93##	2.23±0.38#

\* $p < 0.05$ ; \*\* $p < 0.01$ ; \*\*\* $p < 0.001$ : significant difference compared to control group 1; # $p < 0.05$ ; ##  $p < 0.01$ ; ###  $p < 0.001$ : significant difference compared to control group 2. **Leuco**: leukocytes; **Lympho**: lymphocytes; **Mono**: monocytes; **Neutro**: neutrophils. Group 1: Distilled water; Group 2: Distilled water + amiodarone; Group 3: silymarin + amiodarone; Group 4: AEMb (125 mg/kg b.w.) + amiodarone; Group 5: AEMb (250 mg/kg b.w.) + amiodarone; Group 6: AEMb (500 mg/kg b.w.) + amiodarone; **AEMb**: aqueous extract of *M. barteri*.

### 2-2-Effects of different treatments on erythrocyte parameters

The administration of amiodarone to rats induced a significant decrease ( $p < 0.05$ ) in erythrocytes and hemoglobin levels compared to control group 1 (Table 4). As for erythrocyte indices such as MCV, MCH, MCHC and hematocrit, a significant decrease ( $p < 0.05$ ) in their level was observed in rats receiving amiodarone compared to control group 1. The pretreatment of rats with AEMb at doses ranging from 125 to 500 mg/kg and silymarin induced a significant increase ( $p < 0.05$ ) in erythrocytes, hemoglobin, hematocrit and erythrocyte indices level compared to the control group 2 (Table 4).



**Table 4:** Effect of the aqueous extract of *Macaranga barteri* leaves on erythrocytes and erythrocyte indices in the experimental rats

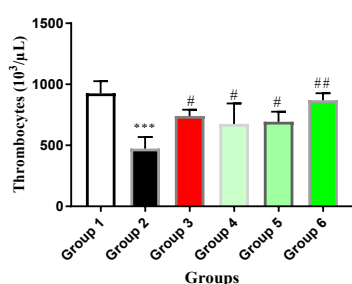
Erythrocyte parameters	Doses in mg/kg b.w					
	Group 1	Group 2	Group 3	Group 4	Group 5	Group 6
<b>RBC</b> (x10 <sup>6</sup> /μL)	7.53±0.32	6.35±0.23**	6.58±0.29	5.93±1.1##	6.82±0.64	7.04±0.43#
<b>Hb</b> (g/dl)	14.8±0.70	11.5± 0.54***	13.2±0.45##	12.3±1.82#	14±1.11###	14.7±0.80###
<b>Hct</b> (%)	42.9±1.95	36.6±1.58***	38.5±1.12##	34.2±6.28#	40.1±3.11###	40.2±2.02###
<b>MCV</b> (fl)	56.9±0.47	54.3±0.74**	58.8±1.32##	57.6±0.76#	59.6±1.61###	57.4±1.9#
<b>MCH</b> (pg)	19.6±0.09	18.1±0.24*	20.11±0.35##	20.6±6.5##	20.8±0.71##	21.2±1.21###
<b>MCHC</b> (g/dl)	34.5±0.19	31.6±0.27**	34.2±0.33##	36.3±11.7###	34.9±1.03##	36.8±1.85###

Values are presented as mean followed by standard error of mean (m ± s.e.m) (n = 6). \*  $p < 0.05$ ; \*\*  $p < 0.01$ ; \*\*\*  $p < 0.001$ : significant difference compared to control group 1 (distilled water group); #  $p < 0.05$ ; ##  $p < 0.01$ ; ###  $p < 0.001$ : significant difference compared to control group 2 (amiodarone). AEMb: aqueous extract of *Macaranga barteri*; **RBC**: red blood cell; **Hb**: hemoglobin; **Hct**: hematocrit; **MCV**: mean corpuscular volume; **MCH**: mean corpuscular haemoglobin; **MCHC**: mean corpuscular haemoglobin concentration  
Group 1: Distilled water; Group 2: Distilled water + amiodarone; Group 3: silymarin + amiodarone; Group 4: AEMb (125 mg/kg b.w.) + amiodarone; Group 5: AEMb (250 mg/kg b.w.) + amiodarone; Group 6: AEMb (500 mg/kg b.w.) + amiodarone. **n=6**.

### 2-3-Variation of thrombocyte levels after the various treatments of the rats

As shown in figure 2, a significant decrease ( $p < 0.001$ ) in thrombocytes level ( $473.3 \pm 38.79.10^3 / \mu\text{L}$ ) is observed in group 2 compared to group 1 (Figure 2). The rats pretreated with silymarin and the different doses of AEMb significantly ( $p < 0.05$ ) reduced the drop in thrombocyte level induced by

amiodarone (control group 2).



**Figure 2:** Variation of thrombocyte levels in rats after different treatments

\*\*\*  $p < 0.001$ : significant difference compared to control group 1.

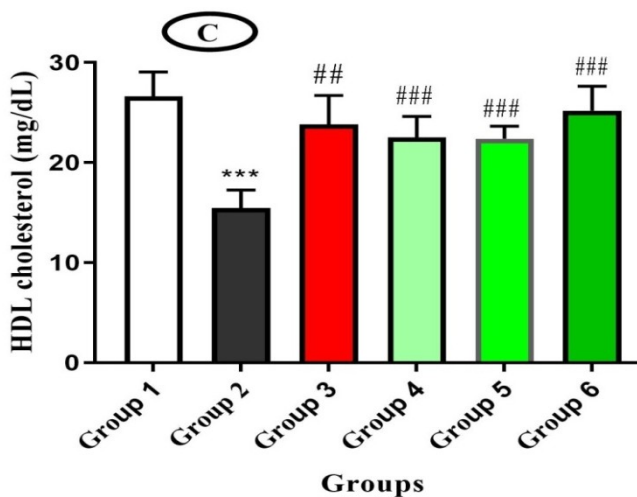
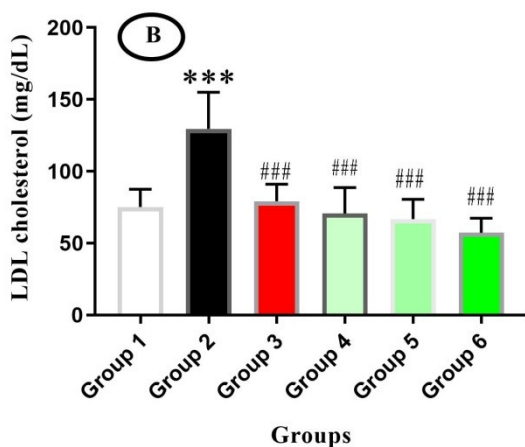
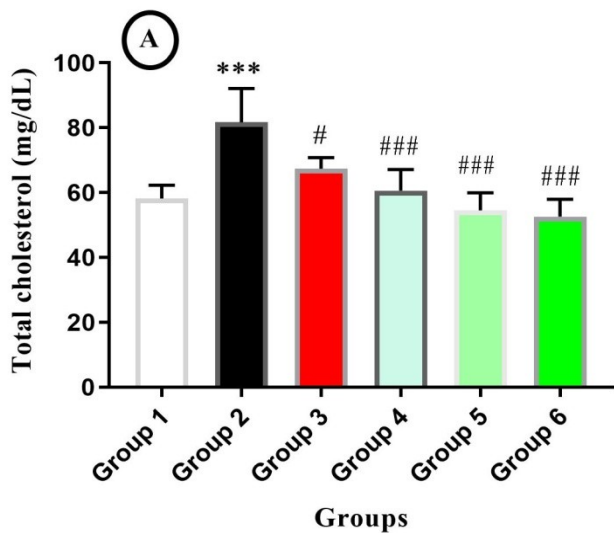
#  $p < 0.05$ ; # #  $p < 0.01$ : significant differences compared to control group 2.

**Group 1:** Distilled water; **Group 2:** Distilled water + amiodarone, **Group 3:** silymarin + amiodarone, **Group 4:** AEMb (125 mg/kg b.w.) + amiodarone, **Group 5:** AEMb (250 mg/kg b.w.) + amiodarone, **Group 6:** AEMb (500 mg/kg b.w.) + amiodarone, **AEMb:** Aqueous extract of

### 3-Effect of the aqueous extract of *Macaranga barteri* leaves on lipid profile

#### 3-1-Effect of different treatments on cholesterol levels in rats

The values of the total cholesterol and LDL-cholesterol levels of control group 1 was  $58.2 \pm 1.66$  mg/dL and  $75.21 \pm 5.04$  mg/dL respectively. The administration of amiodarone led to a very significant ( $p < 0.001$ ) increase in serum total cholesterol levels ( $81.7 \pm 4.23$  mg/dL) and LDL ( $130.44 \pm 10.04$  mg/dL) compared to those of the control group 1 (Figures 3-A and B). The pretreatment of the rats with AEMb at doses ranging between 125 and 500 mg/kg b.w. and silymarin caused a significant decrease ( $p < 0.05$ ) of these parameters increased with amiodarone from  $60.7 \pm 2.64$  mg/dL (AEMb, 125 mg/kg) to  $52.6 \pm 2.18$  mg/dL (AEMb, 500 mg/kg) and  $67.35 \pm 2.36$  mg/dL (silymarin) for total cholesterol. As for LDL-cholesterol, its serum level, which had increased, dropped significantly ( $p < 0.05$ ) from  $70.7 \pm 7.35$  to  $57.18 \pm 14.19$  mg/dL respectively from 125 mg/kg to 500 mg/kg b.w. of AEMb, and  $59.2 \pm 4.84$  mg/dL (silymarin) compared to the control group 2 (Figure 3-B). The HDL-cholesterol, in control rats' group 1 was  $26.6 \pm 2.47$  mg/dL. Amiodarone caused a very significant drop ( $p < 0.001$ ) in HDL-cholesterol from its normal value to  $15.47 \pm 1.79$  mg/dL. Oral administration of AEMb extract and silymarin significantly increased ( $p < 0.05$ ) the HDL-C level lowered by amiodarone and reached  $25.2 \pm 2.43$  mg/dl at 500 mg/kg b.w. of AEMb (Figure 3-C).



**Figure 3:** Variation of the cholesterol levels in the different groups of rats.

\*\*\*  $p < 0.001$ : significant difference compared to the control group 1 (distilled water).

#  $p < 0.05$ ; ###  $p < 0.001$ : significantly difference compared to control group 2 (amiodarone).

**A:** Total-cholesterol; **B:** LDL-cholesterol; **C:** HDL-cholesterol  
**Group 1:** Distilled water; **Group 2:** Distilled water + amiodarone, **Group 3:** sylimarin + amiodarone, **Group 4:** AEMb (125 mg/kg b.w.) + amiodarone, **Group 5:** AEMb (250 mg/kg b.w.) + amiodarone, **Group 6:** AEMb (500 mg/kg b.w.) + amiodarone

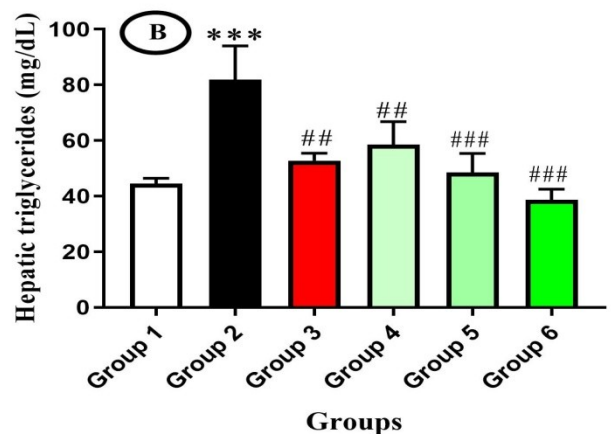
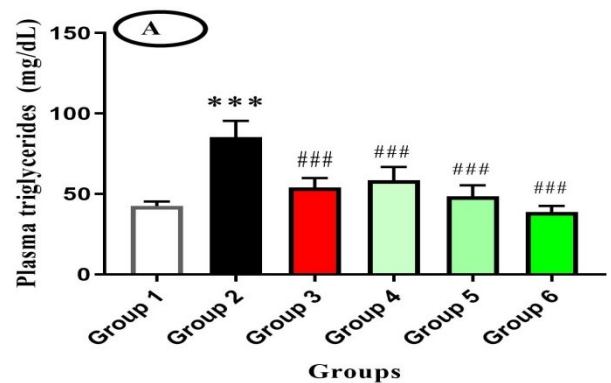
amiodarone, **AEMb:** Aqueous extract of *Macaranga barteri* leaves,  $n = 6$ , number of rats.

**3-2-Effect of the different treatments on plasma and hepatic triglyceride levels**

The plasma triglyceride level of the control group was  $44.51 \pm 0.78$  mg/dL. This parameter increased significantly ( $p < 0.001$ ) to  $81.95 \pm 4.94$  mg/dL in control group 2 compared to the control group 1. In rats pretreated with silymarin and AEMb at doses ranging from 125 to 500 mg/kg b.w., a significant decrease ( $p < 0.001$ ) in plasma triglyceride level was observed compared to the control group 2. This level reached  $57.77 \pm 2.53$  mg/dL for silymarin,  $58.57 \pm 3.34$  mg/dL,  $46.57 \pm 2.78$  mg/dL and  $38.67 \pm 1$ , 50 mg/dL for AEMb at the respective doses of 125; 250 and 500 mg/kg b.w. (Figure 4-A).

As regards the level of hepatic triglyceride, it was  $42.5 \pm 1.15$  mg/dL in control group 1 (Figure 4-B). However, the rats of the control group 2, had a very significant level ( $p < 0.001$ ) of hepatic triglyceride compared to the control group 1. This level was  $85.3 \pm 4.16$  mg/dL. The pretreatment of rats with the

ifferent doses of AEMb induced a very significant decrease ( $p < 0.01$ ;  $p < 0.001$ ) in hepatic triglyceride levels compared to those of the control group 2. These values were  $58.8 \pm 2.53$  (AEMb, 125 mg/kg),  $48.6 \pm 2.79$  (AEMb, 250 mg/kg) and  $38.67 \pm 3.34$  mg/dL (AEMb, 500 mg/kg). As for silymarin (Group 3), a significant decrease ( $p < 0.001$ ) in triglyceride level ( $52.6 \pm 2.53$  mg/dL) was also observed compared to the control group 2 (figure 4-B).



**Figure 4:** Effect of the different treatments on triglyceride levels in rat

**A:** Plasma triglycerides; **B:** Hepatic triglycerides

\*\*\*  $p < 0.001$ : significant difference compared to control group 1 (distilled water).

##  $p < 0.01$ ; ###  $p < 0.001$ : significant difference compared to control group 2 (amiodarone).

**Group 1:** Distilled water; **Group 2:** Distilled water + amiodarone, **Group 3:** silymarin + amiodarone, **Group 4:** AEMb (125 mg/kg b.w.) + amiodarone, **Group 5:** AEMb (250 mg/kg b.w.) + amiodarone, **Group 6:** AEMb (500 mg/kg b.w.) + amiodarone, **AEMb:** Aqueous extract of *Macaranga barteri* leaves,  $n = 6$ , number of rats.

### 3-3-Effect of the aqueous extract of *Macaranga barteri* leaves on alkaline phosphatase, total proteins, bilirubins, AST and ALT

As shown in Table 5, the level of serum alkaline phosphatase (ALP) in group 1 rats was  $368 \pm 56.4$  U/L. As for the group of rats intoxicated with amiodarone (Group 2), the level of ALP recorded was  $802 \pm 48.2$  U/L; this value was significantly high ( $p < 0.001$ ) compared to the control group 1. When rats were

pretreated with AEMb, a significant decrease ( $p < 0.001$ ) in serum ALP level ( $320 \pm 48$  U/L) compared to the control group 2 was observed at 500 mg/kg b.w.

Regarding the serum levels of total proteins and total and conjugated bilirubins, to rats without any treatment, values were  $5.52 \pm 0.31$  g/dL (total protein),  $0.88 \pm 0.04$  mg/dL (total bilirubin) and  $0.39 \pm 0.03$  mg/dL (conjugated bilirubin). However, in control group 2, the level of total protein ( $6.22 \pm 0.39$  g/dL), total bilirubin ( $1.2 \pm 0.06$  mg/dL) and conjugated bilirubin ( $1.1 \pm 0.07$  mg/dL), recorded, were increased significantly ( $p < 0.05$ ) compared to the control group 1. When rats were pretreated with AEMb (500 mg/kg), a significant decrease ( $p < 0.05$ ) in serum levels of total bilirubin ( $0.52 \pm 0.07$  mg/dL), conjugated bilirubin ( $0.35 \pm 0.03$  mg/dL), were recorded compared to control group 2. As for total protein level, it dropped significantly ( $p < 0.05$ ) from  $5.40 \pm 0.1$  g/dl (AEMb 125 mg/kg) to  $1.01 \pm 0.10$  (AEMb 500 mg/kg) and  $5.44 \pm 0.38$  g/dL (silymarin) compared to control rats that received amiodarone only.

The control group rats showed  $123 \pm 6.29$  U/L and  $63.4 \pm 2.32$  U/L as serum AST and ALT levels respectively. In contrast, in animals intoxicated with amiodarone, serum AST and ALT levels significantly ( $p < 0.001$ ) increased compared to control group 1. These levels were  $221 \pm 13.2$  and  $102 \pm 2.6$  U/L for AST and ALT respectively. The pretreatment of rats with silymarin and AEMb at doses ranging from 125 to 500 mg/kg induced a significant decrease ( $p < 0.05$ ) in serum AST and ALT levels compared to the control group 2 (Table 5).

Table 5: Variation of some biochemical parameters after various treatments in rats

Groups	Dose (mg/kg)	TP (g/dl)	ALP (U/L)	TB (mg/dl)	CB (mg/dl)	AST (U/L)	ALT (U/L)
Control group 1		$5.52 \pm 0.31$	$368 \pm 56.4$	$0.88 \pm 0.04$	$0.39 \pm 0.03$	$123 \pm 6.29$	$63.4 \pm 2.32$
Control group 2	200	$6.22 \pm 0.39^*$	$802 \pm 48.2^{***}$	$1.2 \pm 0.06^{**}$	$1.11 \pm 0.07^{**}$	$221 \pm 13.2^{***}$	$102 \pm 2.6^{***}$
Silymarin	100	$5.44 \pm 0.38^{##}$	$335 \pm 13.6^{###}$	$0.79 \pm 0.04^{\#}$	$0.29 \pm 0.08^{###}$	$115 \pm 13.6^{###}$	$68.2 \pm 4.55^{##}$
AEMb	125	$5.40 \pm 0.22^{##}$	$353 \pm 61.1^{###}$	$0.74 \pm 0.05^{\#}$	$0.23 \pm 0.04^{###}$	$122 \pm 12.7^{##}$	$68.6 \pm 6.69^{##}$
	250	$3.24 \pm 0.17^{##}$	$354 \pm 54.4^{###}$	$0.68 \pm 0.06^{\#}$	$0.28 \pm 0.02^{###}$	$118 \pm 9.4^{###}$	$60 \pm 8.19^{##}$
	500	$1.01 \pm 0.10^{##}$	$320 \pm 48^{###}$	$0.52 \pm 0.07^{\#}$	$0.35 \pm 0.03^{###}$	$109 \pm 13.3^{###}$	$58 \pm 5.37^{###}$

\*  $p < 0.05$ ; \*\*  $p < 0.01$ ; \*\*\*  $p < 0.001$ : significant difference compared to the control group 1 (distilled water). #  $p < 0.05$ ; ##  $p < 0.01$ ; ###  $p < 0.001$ : significant difference compared to the control group 2 (amiodarone). TP: total protein; ALP: alkaline phosphatase; TB: total bilirubin; CB: conjugated bilirubin; AST and ALT are transaminases. **Group 1:** Distilled water; **Group 2:** Distilled water + amiodarone, **Group 3:** silymarin + amiodarone, **Group 4:** AEMb (125 mg/kg b.w.) + amiodarone, **Group 5:** AEMb (250 mg/kg b.w.) + amiodarone, **Group 6:** AEMb (500 mg/kg b.w.) + amiodarone, **AEMb:** Aqueous extract of *Macaranga barteri* leaves,  $n = 6$ , number of rats.

### Discussion

The evaluation of the preventive effect of the aqueous extract of *Macaranga barteri* leaves (AEMb) at doses ranging from 125 to 500 mg / kg b.w. on amiodarone induced hepatic steatosis revealed that this extract possessed a real preventive potential. Indeed, the rats pretreated with AEMb presented granite livers, brownish brown or variegated in color, normal consistency, soft and firm to the touch, close to the appearance of the liver of control rats which received distilled water. The relative liver weight percentage was close to that of the control rats (distilled water). These results suggest that the extract protected the liver. AEMb also induced an increase in animals' weight. The observed weight gain could be due to the proper functioning of the repaired liver following the administration of the extract. These results are similar to those reported by [17] who observed finely granulated livers, small lesions after repeated administration of 250 mg/kg bw of the aqueous

extract of *Nauclea latifolia* to mice intoxicated with carbon tetrachloride. The intraperitoneal administration of amiodarone (200 mg/kg b.w) three times a day caused changes in liver color, weight and relative liver weight, as well as the appearance of the liver of rats compared to untreated ones. These symptoms are signs of fatty liver disease according to [18]. It is well known that amiodarone is a class III antiarrhythmic agent prescribed for the treatment of dilated cardiomyopathies and ventricular tachycardias. However, its high dose or long-term use leads to hepatocellular necrosis with inflammatory cell infiltrations and lipidosis [19]. The pretreatment of animals with AEMb protected the liver from the effects of amiodarone. AEMb could therefore be endowed with hepato-protective potential.

The increase in leukocyte count and leukocyte indices in animals pretreated with silymarin and AEMb compared to those treated with amiodarone could be explained by the fact

that these substances (extract and silymarin) would either protect the production of these cells or prevent their damage by amiodarone. The leukocytosis seen in rats treated with amiodarone may be due to bone marrow aggression or toxic effects on these cells. Hematologic analysis also revealed a significant decrease in erythrocyte, hemoglobin and hematocrit levels in animals intoxicated with amiodarone compared to healthy animals and those treated with silymarin and AEMb. These results suggest that AEMb would have positive impact on this cell line by impeding the noxious effects of amiodarone. The results of this study also revealed an increase in thrombocyte count level in rats treated with AEMb and silymarin compared to those treated with amiodarone alone. Prolonged administration of amiodarone causes hepatic dysfunction resulting in thrombocytopenia [19]. This fact could be due to the disturbing effect of amiodarone on thrombopoietin, a regulatory hormone of thrombocyte produced by hepatocytes. Thus, by protecting hepatocytes, AEMb could annihilate this effect of amiodarone. The high serum level of these enzymes is therefore an indication of intoxication [20]. The pretreatment of rats with AEMb (125, 250 and 500 mg / kg b.w.) followed by seven days administration of amiodarone resulted in a significant decrease in hepatic enzyme biomarkers. The decrease in serum AST, ALT and ALP is therefore a sign of improved liver function. This observation is the same with serum non enzymatic hepato-

biomarkers and total proteins. Therefore, these results strengthen the fact that AEMb effectively protected hepatocytes against hepatic damage from amiodarone. This decrease in the serum level of these biomarkers can be explained by the richness of this extract in secondary metabolites such as phenols, tannins, alkaloids and flavonoids [11].

Indeed, according to [21], these compounds have hepatoprotective activity. These results corroborate to those obtained by [22]. These authors indicated that aqueous extract of *Cynara scolymus* leaves called artichoke decrease hepatic enzyme biomarkers in patients with non-alcoholic steatohepatitis. As for lipid biomarkers such as triglycerides (plasma and hepatic) and LDL cholesterol, their increase in animals treated with amiodarone could be due to energy production impairment, the result of mitochondrial dysfunction and decreases of fat oxidation causing steatosis or cellular dysfunction [23]. Pretreatment of animals with silymarin and AEMb resulted in a significant decrease in these lipid biomarkers. According to [24], silymarin exerts a protective effect against a toxin by preventing the latter from crossing hepatocyte membranes and inhibits the effects of tumor necrosis factor  $\alpha$  (TNF $\alpha$ ) which exacerbate lipid peroxidation. It can be hypothesized that AEMb which protected the liver use the same mechanism. However, additional experiments are necessary to confirm this hypothesis.

## Conclusion

This study revealed the preventive effect of the aqueous extract of *M. barteri* leaves (AEMb) in non-alcoholic hepatic steatosis induced by amiodarone in rats. The

traditional use of this plant in the treatment of hepatic disorders is therefore justified.

## Acknowledgment

The authors are grateful to the Laboratory of Physiology, Pharmacology and Pharmacopoeia (University Nangui Abrogoua) staff for their encouragement and technical assistance during these investigations.

## Funding

No funding sources

## Ethical approval

This study followed the experimental animal protection protocols of the European Council on Legislation 2012/707 / EU.

## Conflict of interest

The authors declare no conflict of interest

## References

1. Adams LA, Lymp JF, St Sauver J, Sanderson SO, Lindor KD, Feldstein A, Angulo P. The natural history of nonalcoholic fatty liver disease: a population-based cohort study. *Gastroenterol*, 2005; 129: 113–121.
2. El-Assal O, Hong F, Kim W, Radaeva S, Gao B. IL-6-deficient mice are susceptible to ethanol-induced hepatic steatosis: IL-6 Protects against ethanol-induced oxydative stress and mitochondrial permeability transition in the liver. *Cel Mol Immunol*, 2004; 1(3): 205-211.
3. Chalasani N, Younossi Z, Lavine J, Dieh A, Brunt E, Cusi K, Charlton M, Sanyal A. "The diagnosis and management of non-alcoholic fatty liver disease: practice guideline by the American Gastroenterological Association, American Association for the study of liver diseases, and American College of Gastroenterology." *Gastroenterol*, 2012; 142 (7): 1592-609.
4. Hauhouot-Attoungbre M, Yayo S, Ake-Edjeme A. Le syndrome métabolique existe-t-il en Côte d'Ivoire, *Immunoanal Biol Spécial*, 2008 ; 23 : 375–378.
5. Yin M, Wheeler M, Kono H, Bradford B, Gal LRM, Luster M, Thurman RG. Essential role of tumor necrosis factor alpha in alcohol-induced liver injury in mice. *Gastroenterol*, 1999 ; 117 (4): 942-952.
6. Kim MS, Pinto SM, Getnet D, Nirujogi, RS, Manda SS, Chaerkady R, Madugundu AK, Kelkar O S, Isserlin R, Jain S, Thomas J K, Muthusamy B, Leal-Rojas P, Kumar P, Sahasrabudhe NA, Shankar SK, Hruban RH, Kerr C L, Bader GD, Iacobuzio-Donahue CA, Gowda H, Pandey A. A draft map of the human proteome. *Nature*, 20 14; 509 (7502): 575-581.
7. WHO, Promoting the role of traditional medicine in health: system: A strategy for the African region. World Health Organization *AFR/RC50/9*, 2002; pp12-15.
8. Oliver-Bever B. Medicinal Plants in Tropical West Africa. *Cambridge University Press*, Cambridge



- London, New York, New Rochelle, Melbourne, Sidney, 1986; pp. 240-245.
9. Adesegun S, Elechi N, Coker H. Antioxidant power of *Macaranga basteri* leaf. *Am J food Technol*, 2007; 2 (6): 543-549.
  10. Ngoumfo R, Ngounou G, Tchamadeu C, Qadir M, Mbazoa C, Begum A. Inhibitory effect of Macabarlerin, a polyoxygenated Ellagitannin from *Macaranga barteri*, on human neutrophil respiratory burst activity. *Journal Natural Products*, 2008; 71: 1906-1910.
  11. Ehilé EH, Goze NB, Kouakou KL, Yapo AP, Ehilé EE. Acute toxicity and gastric anti-ulcer activity of an aqueous extract of the leaves of *Macaranga barteri* Müll.Arg (Euphorbiaceae) on rat models. *Journal of Medicinal Plants Research*, 2018; 12 (9) 96-105.
  12. OECD Series on the principles of good laboratory practice and verification of compliance with these principles. ENV / MC / CHEM, 1998; (98) 17: 22-23.
  13. Zirihi GN, Kra AKM, Guédé-Guina F. Evaluation de l'activité Antifongique de *Microglossa pyrifolia* (LAMARCK) O. KUNTZE (Asteraceae) « PYMI » sur la croissance *in vitro* de *Candida albicans*. *Revue de Médecine et de Pharmacopées Africaines*, 2003; 17: 11-18.
  14. Saleem N, Riaz H, Ahmad M, Mehmood Y, Raza SA, Khan S, Anwar R, Kamran SH. Hepatoprotective effect of *Crocus sativus* on Amiodarone-induced liver toxicity. *British Journal of Pharmaceutical Research*, 2016; 12(4): 1-11.
  15. Tietz N. Fundamentals of Clinical Chemistry, Edition World Book Saunders Co. Philadelphia 3, 1983; p 425-427.
  16. Islam R, Alam AH, Rahman BM, Salam KA, Hossain A, Baki A, Sadik G. Toxicological studies of two compounds isolated from *Loranthus globosus* Roxb. *Pak. Journal of Biological Sciences*, 2007; 10: 2073-2077.
  17. Youssouf O. Etude de l'activité des extraits aqueux de plantes hépatotropes sur le foie de souris soumises à une intoxication" aigüe au tétrachlorure de carbone. *Thèse de 3<sup>ème</sup> cycle en Science Biologiques Appliquées de l'université de Ouagadougou*, 1999 ; p.109.
  18. Atiq M, Davis J, Lamps L, Beland S, Rose J. Amiodarone induced liver cirrhosis. report of two cases. *Journal of Gastrointestinal and Liver Diseases*, 2009; 18 (2): 233-235.
  19. Jacobs G, Calvert C, Kraus M. Hepatopathy in 4 dogs treated with amiodarone. *Journal of Veterinary Internal Medicine*, 2000; 14 (1): 96-99.
  20. Drotman RB, Lawhorn GT. Serum enzymes as indicators of chemical induced liver damage. *Drug and Chemical Toxicology*, 1978; 1: 163-171.
  21. Ravichandran S, Rahul C, Thangaraj P. Hepatoprotective effect of *Rhodiola imbricate* rhizome against paracetamol-induced liver toxicity in rats. *Saudi Journal of Biological Science*, 2014 ; 21 : 409-416.
  22. Vajiheh R, Mostafa N, Zavoshy R, Seyed A, Rezadoost Asghar M. The Effect of Artichoke leaf extract on alanine aminotransferase and aspartate aminotransferase in the Patients with Nonalcoholic Steatohepatitis. *International Journal of Hepatology*, 2016; p6.
  23. Berson A. Hépatotoxicité médicamenteuse par atteinte mitochondriale. *Hépatogastroenterology*, 2005 ; 12 (3) :191-198.
  24. Fraschini F, Demartini G, Esposti D. Pharmacology of silymarin. *Clinical Drug Investigation*, 2002; 22 (1): 51-65.