



# WORLD JOURNAL OF CURRENT MEDICAL AND PHARMACEUTICAL RESEARCH

www.wjcmpr.com

ISSN: 2582-0222

## Recurrent pleural effusion in patient with liver cirrhosis-a case report

Diah Pradnya Paramita\*<sup>1</sup>, Putu Indri Widiani<sup>1</sup>, Wayan Sunaka<sup>1</sup>

Department of Internal Medicine, Wangaya Regional Hospital, Denpasar, Bali, Indonesia

### Abstract

Liver cirrhosis is caused by necrosis of liver cells leading to fibrosis and nodule formation. Structural abnormalities of the liver causing impaired hepatocyte function and portal hypertension. Hepatic hydrothorax is a less common pulmonary complication of portal hypertension. We present a 47 years old man with liver cirrhosis and recurrent massive pleural effusion. Diagnosis can be challenging because it can be associated with pulmonary or systemic disorders. Pleural fluid analysis is necessary to differentiate transudate or exudate as the cause of pleural effusion. Thoracentesis is done to reduce the complaints experienced by the patient.



#### Article History:

Received on: 04.06.2021

Revised on: 12.06.2021

Accepted on: 30.08.2021

#### Keywords:

Liver cirrhosis, Pleural effusion,

Hepatic Hydrothorax.

#### \*Corresponding Author

Name: Diah Pradnya Paramita

Email: [pradnyadiah@yahoo.com](mailto:pradnyadiah@yahoo.com)

DOI: <https://doi.org/10.37022/wjcmpr.v3i4.186>

This article is licensed under a Creative Commons Attribution-NonCommercial 4.0 International License. Copyright © 2021 Author(s) retain the copyright of this article.



### Introduction

Liver cirrhosis characterized by the formation of scarring and regenerative nodules in liver parenchyma due to inflammation in parenchyma. The normal liver parenchyma was replaced by the scar tissue from the necrotic liver. These scars block the portal flow of blood to organs. Some etiologies are viral/infectious, metabolic disorders, cholestatic, and vascular problem [1]. Chronic liver disease causes 2 million deaths per year and liver cirrhosis is the 11th leading cause of death in the world [2]. Portal hypertension and hyperdynamic circulation due to the progression of liver parenchymal cell damage were the main cause of morbidity and mortality in chronic liver disease patients is [3].

Portal hypertension occurs due to scarring of fibrous tissue, thereby blocking portal venous outflow and increasing hepatic resistance. In portal hypertension there is a small amount of a vasodilator agent (nitric oxide) intrahepatically causing sinusoidal vasoconstriction. Excessive amounts of nitric oxide present in the extrahepatic (splanchnic and systemic circulation) causing splanchnic vasodilation. Collaterals develop to balance the increased intrahepatic resistance and contribute to hyperdynamic circulation by increasing venous return to the heart. Liver cirrhosis may affect many organs such as gastrointestinal, hematologic, renal, skin, endocrine, nail changes, and pulmonary [3].

Hepatic hydrothorax occurs in 5 to 10% of cirrhotic patients with portal hypertension which is a less common complication in the lung. The portal hypertension and the consequent splanchnic vasodilation have an important role in the formation of both the ascites and the hepatic hydrothorax. Hepatic hydrothorax defined as significant pleural effusion more than 500 ml, usually presents unilateral most often right-sided, associated with the presence or absence of clinically

detectable ascites, without other causes such as pulmonary or cardiac diseases [4].

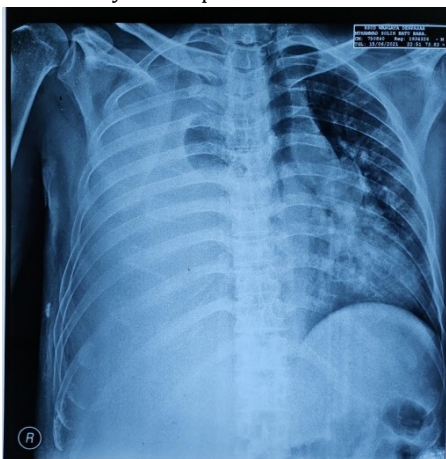
Diagnosis of hepatic hydrothorax may be considered clinically in cirrhotic patients with portal hypertension who have a pleural effusion with or without ascites and the exclusion of cardiopulmonary disease. Restriction of salt intake and diuretics is the initial treatment for hepatic hydrothorax. Study revealed about 25% of patients is refractory to it and have rapid recurrences. Definitive treatment for recurrent hepatic hydrothorax in end stage liver disease is a liver transplant but it may take time. Several other primary managements can be done to reduce complaints [5].

### Case Report

A 47-year-old man was admitted with complaints of shortness of breath since 4 days ago. Shortness of breath was felt continuously and did not improve with a change in position. Shortness of breath was accompanied by a dry cough, weakness throughout the body, nausea lead to decrease of appetite and a feeling of fullness in the stomach,. Other complaints were continuously pain in the upper right abdomen and melena with a solid consistency of feces since 1 day before admitted, patient also had disturbance in sleep. The patient denied having fever or cold sweats at night. History of smoking, alcohol consumption was denied. The patient was previously hospitalized with liver cirrhosis, hepatoma, right pleural effusion, and ascites three weeks before his current admission. Out of the hospital the patient routinely consumes anti-diuretic drugs (furosemide and spironolactone), ursodeoxycholic acid, and curcuma On examination, the patient was conscious, vital signs were within normal limits, oxygen saturation was 99% with nasal cannula 4 liters per minute. The patient had icterus on both of sclera. Chest examination revealed decreased right

lung sounds and dull on percussion without any ronchi or wheezing. Liver was palpable 3 fingers under the arcus costae, hard in consistency, with ridged edges. Abdomen found slightly distended, dull on percussion, undulation test was negative. No other signs of chronic liver disease or peripheral edema were seen. Laboratory examination revealed normal mild normochromic normocytic anemia Hb=12.9 g/dl; MCV=82.3 fL; MCH=30.8 pg, normal leucocyte  $8.91 \times 10^3/\mu\text{L}$ , and normal platelet  $189 \times 10^3/\mu\text{L}$ . Neutrophil/lymphocyte ratio was found normal, NLR ratio=1.26. Liver enzyme test showed transaminitis AST=333; ALT=88. Protein analysis showed low albumin level 2.4 g/dl. Pleural fluid analysis was performed with result of slightly cloudy yellow color, no clot was found, PMN was  $0.012 \times 10^3/\text{ul}$ , MN was  $0.368 \times 10^3/\text{ul}$ , leucocyte was  $0.380 \times 10^3/\text{ul}$ , rivalta test was negative, glucose was 105 mg/dL, protein was 4.1 g/dL, low albumin level 2.07 g/dL, and normal LDH 271 U/L. Chest x-ray revealed massive right pleural effusion (Figure 1). This patient had undergone alpha fetoprotein level (AFP) test on the previous admission, it revealed to be high 527.44 ng/mL.

Based on the clinical and laboratory findings we diagnosed this patient as hepatic hydrothorax. The patient started therapy branched-chain amino acid infusion along with normal saline and 5% dextrose, third-generation cephalosporin antibiotic, proton pump inhibitor, and antiemetic intravenously. A combination of loop diuretic and K sparing diuretic were given both intravenously and orally. Another treatment such as sucralfate, lactulosa, and pain killer were given orally. The patient underwent 4 times pleural fluid puncture with total fluid accumulation of 3020 ml. Patient discharged with clinical improvement in 7 days of hospitalization.



**Fig 01: Massive right pleural effusion**

## Discussion

We present a case of 47 years old man suffering liver cirrhosis CTP class C and experienced recurrent massive right pleural effusion defined as hepatic hydrothorax. A total of 3 litres of fluid was obtained in the right pleura via thoracentesis. This case is suggestive as hepatic hydrothorax due to the complication of portal hypertension in liver cirrhosis, as this patient has neither heart nor lung disease. The underlying cause of liver cirrhosis in this patient remains uncertain. Hepatic hydrothorax is a massive pleural effusion usually on the right side with a transudate fluid volume of more than 500 ml, without cardiac or pulmonary abnormalities. He also suspected having hepatocellular carcinoma based on the high

ALP level (527.44 ng/mL) as a marker of liver malignancy, but this suspicion better equipped with imaging examination [6]. Liver cirrhosis is a risk factor for developing hepatocellular carcinoma (HCC) [7].

There are three reasonable mechanisms as a cause of hepatic hydrothorax such as a diaphragmatic defect that causes ascitic fluid to move into the pleura, a decrease in colloid osmotic pressure as a result of hypoalbuminemia, and lymphatic leakage from the thoracic tract [8]. Leakage of ascitic fluid through a diaphragmatic defect best explains the pathogenesis of hepatic hydrothorax. The accumulation of ascitic fluid causes an increase in intra-abdominal pressure and causes small herniation of the peritoneum into the pleural cavity (pleuroperitoneal blebs). The anatomical proximity of the liver and the diaphragm causing hepatic hydrothorax occur more frequent on the right side. The proximity of the diaphragm to the abdominal cavity anatomically and negative intrathoracic pressure causes the movement of fluid from the abdominal cavity to the pleural cavity resulting in pleural effusion. Microscopically, herniation occurs due to discontinuity of the collagen bundles in the diaphragmatic tendon [9].

Diagnostic lab tests for pleural effusion are performed to confirm the diagnosis and rule out other possibilities, such as infection. Several laboratory parameters assessed from pleural fluid and blood serums including cell count, protein, albumin, glucose and lactate dehydrogenase (LDH). [4,10]. The composition of hepatic hydrothorax is transudative similar to the ascitic fluid [4]. In this case patient was indicated a transudate fluid based on the patient's total nucleated cell count  $<1000/\text{ml}$ , LDH  $<2/3$  upper limit of serum LDH, low pleural fluid protein  $<2.5 \text{ g/dL}$ , negative on rivalta and pleural fluid glucose to blood glucose ratio  $>0.5$  [11]. The protein in pleural fluid was high in this case potentially caused by the diuretic therapy. Concentrated pleural effusion due to diuretic causing a higher level of protein or LDH in pleural fluid, therefore leading to a misclassification as an exudate [12]. The weakness of this case report is that several parameters of blood laboratory examination as a comparison for pleural fluid analysis were not performed.

Several approaches to the management of hepatic hydrothorax such as to reduce the formation of ascites (reducing salt and fluid intake, diuretic drugs, somatostatin, transjugular intrahepatic portosystemic shunts (TIPS), liver transplant); prevention of ascitic fluid transfer across the diaphragm (repair of the defect, paracentesis); reduce pleural fluid (thoracentesis, pleural catheter); and pleurodesis [13]. The initial managements of hepatic hydrothorax including low-salt diet and a combination of loop diuretic (furosemide) with potassium-sparing diuretic regiments (spironolactone). Thoracentesis is a less invasive procedure that is mandatory in patients who have recurrent or refractory hydrothorax to relieve dyspnea and remove the excess pleural fluid. Pleural fluid removal should not exceed 2L in a single procedure in order to avoid the risk of hypotension or re-expansion of pulmonary edema [14]. However, a prospective study involving 185 patients reported only a few patients developed complication of thoracentesis such as pulmonary edema and radiographic abnormality. Other complications of thoracentesis include pain at the puncture site of the pneumothorax,

hemothorax, soft tissue infection, empyema, air embolic hemoptysis, and subcutaneous emphysema [15].

The complications of liver cirrhosis are hepatic encephalopathy, rupture of esophageal varices, and HCC. These complications and the presence of a hepatic hydrothorax are predictive factors for poor long-term outcome and mortality, except in those undergoing TIPS or liver transplantation. A recent study revealed that 75.9% of patients who developed pleural effusion due to cirrhosis of the liver died within 3 years since the symptoms first appeared. The comorbidities including old age, pneumonia, are also risk factors for mortality in cirrhotic patients with pleural effusion requiring drainage [16].

### Conclusion

Cirrhotic patients with portal hypertension may suffer a complication that occurs in the lung defined as hepatic hydrothorax. Hepatic hydrothorax was a massive pleural effusion which can recurrent and does not respond to the diuretic oral therapy. In this case we present 47 years old man with recurrent hepatic hydrothorax related to liver cirrhosis and underwent 4 times thoracentesis with total volume more than 3 litres. Cirrhotic patients with pleural effusion may receive thoracentesis for symptom control in the short-term.

### Declarations

Funding: No funding sources

Conflict of interest: None declared

Ethical approval: Not required

### Acknowledgement

I would like to thank the internal medicine supervisor and the entire medical team for their supports in this case report.

### References

1. Suva M. Review article A Brief Review on Liver Cirrhosis: Epidemiology, Etiology, Pathophysiology, Symptoms, Diagnosis and Its Management. *Mol Pharmacol*. 2014;(2):1–5.
2. Asrani SK, Devarbhavi H, Eaton J, Kamath PS. Burden of liver diseases in the world. *Hepatology*. 2019;70(1):151–71.
3. Sharma B, John S. *Hepatic Cirrhosis*. StatPearls Publishing LLC; 2020.
4. Krok KL, Cardenas A. Hepatic hydrothorax. *Semin Respir Crit Care Med*. 33(1):3–10.
5. José M P. Management of refractory hepatic hydrothorax. *Curr Opin Pulm Med*. 20(4):352–7.
6. Omata M, Cheng AL, Kokudo N, Kudo M, Lee JM, Jia J, et al. Asia–Pacific clinical practice guidelines on the management of hepatocellular carcinoma: a 2017 update. *Hepatology*; 2017;11(4):317–70.
7. Chedid MF, Kruehl CRP, Pinto M a, Grezzana-Filho TJM, Leipnitz I, Kruehl CDP, et al. Review Article Hepatocellular Carcinoma: Diagnosis and Operative Management. *Arqu Brasi Cir Dig*. 2017;30(4):272–8.
8. Roussos A, Philippou N, Mantzaris GJ, Gourgouliannis KI. Hepatic hydrothorax: Pathophysiology diagnosis and management. *J Gastroenterol Hepatol*. 2007;22(9):1388–93.

9. Huang PM, Chang YL, Yang CY, Lee YC. The morphology of diaphragmatic defects in hepatic hydrothorax: Thoracoscopic finding. *J Thorac Cardiovasc Surg*. 2005;130(1):141–5.
10. Lv Y, Han G, Fan D. Hepatic hydrothorax. *Ann Hepatol*. Elsevier; 2018;17(1):33–46.
11. Karkhanis VS, Joshi JM. Pleural effusion: Diagnosis, treatment, and management. *Open Access Emerg Med*. 2012;4:31–52.
12. Mercer RM, Corcoran JP, Porcel JM, Rahman NM, Psallidas I. Interpreting pleural fluid results. *Clin Med J R Coll Physicians London*. 2019;19(3):213–7.
13. Singh A, Bajwa A, Shujaat A. Evidence-based review of the management of hepatic hydrothorax. *Respiration*. 2013;86(2):155–73.
14. C SS. Reexpansion pulmonary edema: a case report and review of the current literature. *Journal of Emergency Medicine*. 2003;24(1):23–7.
15. Kopman DF, Berkowitz D, Boiselle P, Ernst A. Large-volume thoracentesis and the risk of reexpansion pulmonary edema. 2007;84(5):61.
16. Hung T-H, Tseng C-W, Tsai C-C, Tseng K-C, Hsieh Y-H. The long-term outcomes of cirrhotic patients with pleural effusion. *Saudi Journal Gastroenterol*. 2018;24(1):46–51.